

---

# The Use of Phosphatidylcholine for Correction of Lower Lid Bulging Due to Prominent Fat Pads

PATRÍCIA GUEDES RITTES, MD

*Clínica Patrícia Rittes, Sao Paulo, Brazil*

---

**BACKGROUND.** Patients with prominent periorbital fat pads often complain of having a persistent "tired" look and seek treatment from their dermatologist.

**OBJECTIVE.** A non-surgical treatment of fat pads.

**METHODS.** Thirty patients were treated for prominent lower eyelid fat pads with phosphatidylcholine injection. Pre- and posttreatment photographs were taken for long-term analysis.

**RESULTS.** A marked reduction of the lower eyelid fat pads was noted over the 2-year follow-up period. There were no recurrences.

**CONCLUSION.** The injection of phosphatidylcholine (250 mg/5 ml) into the fat pads is a simple office procedure that may postpone or even substitute for lower eyelid blepharoplasty.

---

INFRAORBITAL FAT PAD herniation results in a prominence of the lower eyelids, causing patients to have a tired and aged appearance. These deformities consist of skin, subcutaneous fat, orbicular muscle, and suborbicular fat. Orbital fat exerts pressure both on the orbital septum and the orbicular muscle, causing a bulge. What appears to be excess skin is often merely the convexity caused by the fat pads appearing under the skin. The precise mechanism of this herniation is controversial. This deformity may be managed by surgical resection or reinsertion of the herniated fat into the orbital cavity.<sup>1-4</sup> Continuous suture of the capsular palpebral fascia maintains it in its original anatomic site. Herniation of the infraorbital fat pad entity must be distinguished from periorbital edema due to medical problems (such as angioneurotic edema or fluid imbalance).

Phosphatidylcholine has been shown to reduce the systemic levels of cholesterol and triglycerides.<sup>5,6</sup> Bobkova et al.<sup>7</sup> showed that upon increasing phosphatidylcholine, the cell membranes improved their receptor properties, augmented their sensitivity to insulin, and accelerated lipolysis. Phosphatidylcholine has also been employed intravenously in patients with cardiac ischemia.<sup>8</sup> A marked reduction of atheromatous plaques without a reduction in plasma cholesterol occurs. Phosphatidylcholine is a bile component and is responsible for the lipids' emulsification from the diet.<sup>9</sup> This article describes the use of phosphatidylcholine injection into the infraorbital fat to reduce the size of infraorbital fat pads.

## Materials and Methods

This study conformed to guidelines of the 1975 Declaration of Helsinki. An informed consent was obtained from all individuals. Preoperative evaluation included examining the size and location of the fat pads. Baseline photographs were obtained. Patients were also examined for any coexisting ocular pathology. The procedure was performed in an outpatient setting with the patient seated. The skin of the lower lid was pulled downward with the forefinger. Gentle pressure was applied over the globe for better visualization of the fat pad. Using a 0.5 inch, 30-gauge needle, 0.4 ml of phosphatidylcholine (250 mg/5 ml) was injected into the infraorbital fat pad. The medication was distributed among the three bulging periorbital fat pads (central, medial, and lateral) based on the individual patient's need. Anesthetics were not utilized in this study.

Thirty patients with varying degrees of bulging fat pads were included in the study. The patient population included 22 women and 8 men, with ages ranging from 30 to 70 years. Injections were given at 15-day intervals to allow for complete resolution of infraorbital swelling. Two patients received a total of four applications, 5 patients a total of three applications, 12 patients a total of two applications, and 11 patients a total of one application. The number of additional injections administered was determined by the clinical response at the end of the 15-day period as observed by the physician and patient.

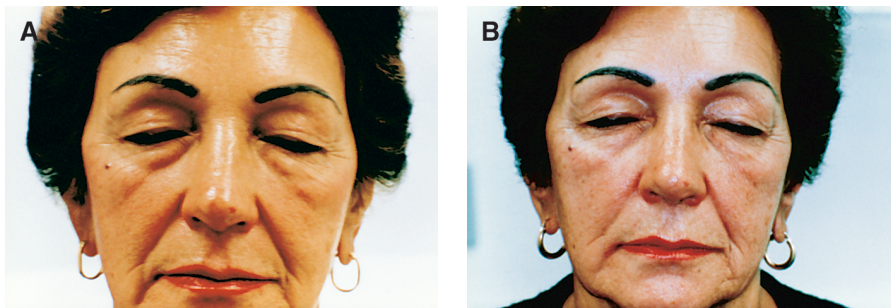## Results

Cosmetic improvement occurred in all patients. Pre- and postprocedure photographs were utilized to document the changes (Figures 1 and 2). All patients complained of mild burning following the injections, which typically lasted about 15 minutes. Immediately following the injections, infiltrative edema and local erythema were noted. Edema of the entire lower lid was noted over the initial 6 hours and persisted for approximately 72 hours.

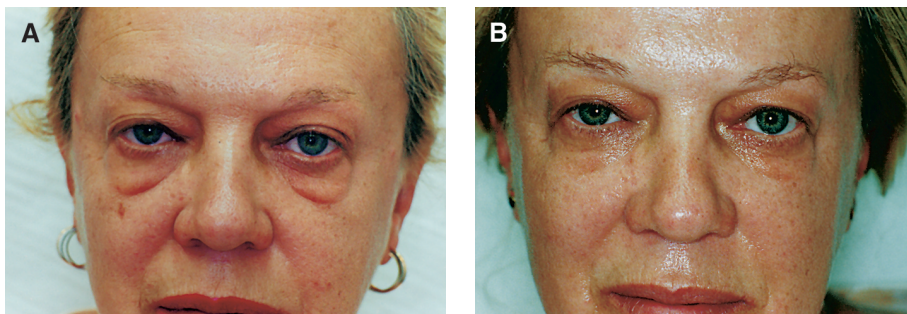
---

P. G. Rittes, MD has indicated no significant interest with commercial supporters.

Address correspondence and reprint requests to: Patrícia Guedes Rittes, MD, Rua José do Patrocínio, 92 Aclimação, São Paulo SP - Brazil, CEP 04108-13, or e-mail: prittes@ruralsp.com.br.



**Figure 1.** A 71-year-old patient with prominent fat pads. B) Postprocedure view after three injections of phosphatidylcholine.



**Figure 2.** A 55-year-old patient with prominent fat pads. B) Postprocedure view after four injections of phosphatidylcholine.

## Discussion

This study offers a nonsurgical alternative for improving “old-looking” eyes by reducing the prominence of bulging infraorbital fat pads through phosphatidylcholine injection. Up until now, all options for treating this entity have been surgically based. Proper patient selection is essential, as this method only treats infraorbital fat. Prominent infraorbital fat pads must be distinguished from other periocular conditions, including prominent malar folds and lax lower eyelid skin.<sup>10</sup>

Because phosphatidylcholine injection does not create scar tissue, ectropion is not a risk. In our experience, the postoperative results offered by phosphatidylcholine injection were as natural in appearance as those obtained from surgical procedures. Postoperative discomfort was also reduced relative to surgery. In addition, no recurrences of protruding infraorbital fat pads were noted.

The cosmetic results observed in this study were satisfactory from both the patients’ and the dermatologists’ point of view. Patient selection is essential for optimal results. This study provides a simple, nonsurgical office-based procedure for treating prominent infraorbital fat pads.

*Acknowledgment* I wish to thank Marcelo Gandelman, MD for his help in editing this article and to A.S. Noel MD,

French dermatologist and pioneer in the surgical excision of fat pads.

Presented at the 54th Brazilian Dermatology Congress, Belo Horizonte, Brazil, September 1999.

## References

1. Parsa FD, Miyashiro MJ, Elahi E, Mirzai TM. Lower eyelid hernia repair for palpebral bags: a comparative study. *Plast Reconstr Surg* 1998;102:7.
2. Sachs ME, Bosnick SL. Correction of true periorbital fat herniation in cosmetic lower lid blepharoplasty. *Aesthetic Plast Surg* 1986;10:111.
3. Loeb R. Fat pad sliding and fat grafting for livelimp lid depression. *Clin Plast Surg* 1981;8:757.
4. Hamra ST. The role of orbital fat preservation in facial aesthetic surgery: a new concept. *Clin Plast Surg* 1996;23:17.
5. Warembourg H, Jaillard J. Experimentation clinique du lipostabil dans le traitement des angiopathies diabetiques. *Lille Med* 1968; XIII(suppl):721-3.
6. Navder KP, Baraona E, Lieber C. Polyenyphosphatidylcholine decreases alcoholic hyperlipemia without affecting the alcohol-induced rise of HDL cholesterol. *Life Sci* 1997;61:1907.
7. Bobkova VI, Lokchina LI, Korsunsk BH, Tamamova GV. Metabolic effect of lipostabilforte. *Kardiologiya* 1989;29:57.
8. Pogozheva AV, Bobkova SN, Samsonov, MA, Vasil'ev, AV. Comparative evaluation of hypolipidemic effects of omega-3 polyunsaturated acids and lipostabil. *Vopr Pitan* 1996;4:31.
9. Montgomery R, Conway T. *Bioquímica*, 5th ed. 1994:249.
10. Farrior RT, Kassir RR. Management of malar folds in blepharoplasty. *Laryngoscope* 1998;108:1659-63.